

Autologous Mesenchymal Stem Cell Transplantation in Stroke Patients

Oh Young Bang, MD, PhD,¹ Jin Soo Lee, MD,¹ Phil Hyu Lee, MD, PhD,¹ and Gwang Lee, PhD²

Mesenchymal stem cell (MSC) transplantation improves recovery from ischemic stroke in animals. We examined the feasibility, efficacy, and safety of cell therapy using culture-expanded autologous MSCs in patients with ischemic stroke. We prospectively and randomly allocated 30 patients with cerebral infarcts within the middle cerebral arterial territory and with severe neurological deficits into one of two treatment groups: the MSC group (n = 5) received intravenous infusion of 1×10^8 autologous MSCs, whereas the control group (n = 25) did not receive MSCs. Changes in neurological deficits and improvements in function were compared between the groups for 1 year after symptom onset. Neuroimaging was performed serially in five patients from each group. Outcomes improved in MSC-treated patients compared with the control patients: the Barthel index ($p = 0.011, 0.017, \text{ and } 0.115$ at 3, 6, and 12 months, respectively) and modified Rankin score ($p = 0.076, 0.171, \text{ and } 0.286$ at 3, 6, and 12 months, respectively) of the MSC group improved consistently during the follow-up period. Serial evaluations showed no adverse cell-related, serological, or imaging-defined effects. In patients with severe cerebral infarcts, the intravenous infusion of autologous MSCs appears to be a feasible and safe therapy that may improve functional recovery.

Ann Neurol 2005;57:874–882

The only specific therapies currently available for stroke are intervention to prevent inappropriate coagulation, surgical procedures to repair vascular abnormalities, and thrombolytic therapy. To date, relatively little attention has been devoted to developing methods to restore function after ischemic stroke.

Recently, the transplantation of bone marrow mononuclear cells (mainly hematopoietic stem cells) achieved clinical efficacy by inducing angiogenesis in patients with myocardial infarction^{1,2} or limb ischemia.³ However, in addition to neovascularization, more complex processes are involved in the restoration of function after ischemic stroke, including neurogenesis and neuronal plasticity. Cell therapy should provide an exogenous supply of cells capable of neurogenesis or modulatory effects, or both, on the environment to enhance plasticity and the survival and differentiation of host cells, but such capacities are limited in hematopoietic stem cells. Therefore, candidate cells other than hematopoietic stem cells are required for cell therapy in stroke patients.

The use of mesenchymal stem cells (MSCs) as therapy for stroke is attractive. MSC therapy has already been used to treat patients with cancer. Moreover, it is conceivable that autologous MSCs could be used,

which would allow immune reactions to be avoided. Preclinical studies have established the potential for MSCs to be a useful and safe treatment for stroke in humans. After peripheral injection, MSCs cross the blood–brain barrier preferentially in areas that have experienced brain damage.^{4,5} Intravenous application of MSCs reduced apoptosis and promoted endogenous cellular proliferation after stroke.⁶ Animal models of stroke have improved with MSC transplantation.^{4,7,8} Although MSC infusion is a promising strategy to augment recovery from stroke, to our knowledge, transplantation of MSCs into stroke patients and the long-term effects of this approach have not been reported. To date, the only report of cell therapy in stroke patients was that in which cell lines derived from human embryonic carcinomas were used.⁹

Transplantation after ex vivo culture expansion of MSCs is mandatory to meet the dose requirements that have been effective in animal models, because few MSCs can be obtained by bone marrow aspiration. We aimed to test the feasibility, efficacy, and safety of cell replacement therapy using cultured autologous MSCs in patients with ischemic stroke. In this study, we evaluated the long-term prognosis and neuroradiological features after intravenous injection of autologous

From the ¹Department of Neurology and ²Brain Disease Research Center, School of Medicine, Ajou University, Suwon, South Korea.

Received Jan 17, 2005, and in revised form Mar 25. Accepted for publication Mar 27, 2005.

Published online May 23, 2005 in Wiley InterScience (www.interscience.wiley.com). DOI: 10.1002/ana.20501

Address correspondence to Dr Young Bang, Department of Neurology, College of Medicine, Ajou University, Woncheon-dong San 5, Paldal-ku, Suwon, Kyungki-do, 442-749, South Korea.
E-mail: nmboy@unitel.co.kr

MSCs in patients with cerebral infarcts within the middle cerebral artery (MCA) territory and with severe neurological deficits.

Patients and Methods

Patients

This study was a randomized, controlled phase I/II clinical trial. The clinical trial protocol and the consent form were approved by the Institutional Review Board for Human Investigation of Ajou University Hospital. We obtained written informed consent from all patients. The overall trial profile is shown in Figure 1.

Patients between 30 and 75 years old were eligible for the study if they had the following characteristics: (1) they had been observed within 7 days of the onset of symptoms; (2) there were relevant lesions within the MCA territory as assessed using diffusion-weighted imaging (DWI); and (3) they had experienced severely disabling deficits that persisted for longer than 7 days (according to the National Institutes of Health Stroke Scale [NIHSS], a score of 7 or more points after 7 days of admission is severe). We excluded patients who met one of the following criteria: lacunar syndrome, hematological causes of stroke, malignant diseases, severe comorbidity, hepatic or renal dysfunction, or unwillingness to participate. Patients were randomly allocated to one of two groups, the MSC or control group, by use of a randomization table. The randomized allocation to groups was performed on the seventh day of admission by a blinded, independent coordinator; after the initial random allocation of patients to treatment groups, experimental procedures were not blinded.

Bone Marrow Aspiration, Isolation of Mesenchymal Stem Cells, and Cell Culture

Bone marrow (5ml) was aspirated, under local anesthesia, from the posterior iliac crest of patients in the MSC group 7 days after admission. Bone marrow mononuclear cells were isolated by Ficoll density centrifugation. Mononuclear cells ($1 \times 10^6/\text{ml}$) were placed in a 175cm^2 flask (Falcon, Franklin Lakes, NJ) and were cultivated in low-glucose Dulbecco modified eagles' medium (Gibco-BRL, Grand Island, NY) containing 10% fetal bovine serum (Hyclone, Irvine, CA) and 1% penicillin/streptomycin (Sigma, St. Louis, MO) in a humidified incubator at 37°C under 5% CO_2 . After 5 days, nonadherent cells were removed by replacing the medium. Attached cells developed into colonies within 5 to 7 days. When these primary cultures of MSCs reached 80% confluence, the cells were harvested using 0.25% trypsin and subcultured. Thus, autologous MSCs were culture expanded to reach 1×10^8 cells/patient within a relatively short period of culture (mean \pm SD: 30.8 ± 5.5 days; range, 23–37 days), as reported previously.¹⁰ Based on mean body mass, 1×10^8 cells/patient is the human dose equivalent to the dose that was effective in a rat model of stroke ($1 \times 10^5 - 3 \times 10^6$ cells/rat).^{4,6-8,11,12}

Cell Preparation for Transplantation

Because stem cells are highly likely to be differentiated, the surface expression of SH-2 (Src homology, CD105) and SH-4 on culture-expanded MSCs was measured using flow cytometry (FACScan; Becton-Dickinson, Rutherford, NJ) before infusion. Every harvest of MSCs showed a homogeneous population of cells with high side and forward scatter

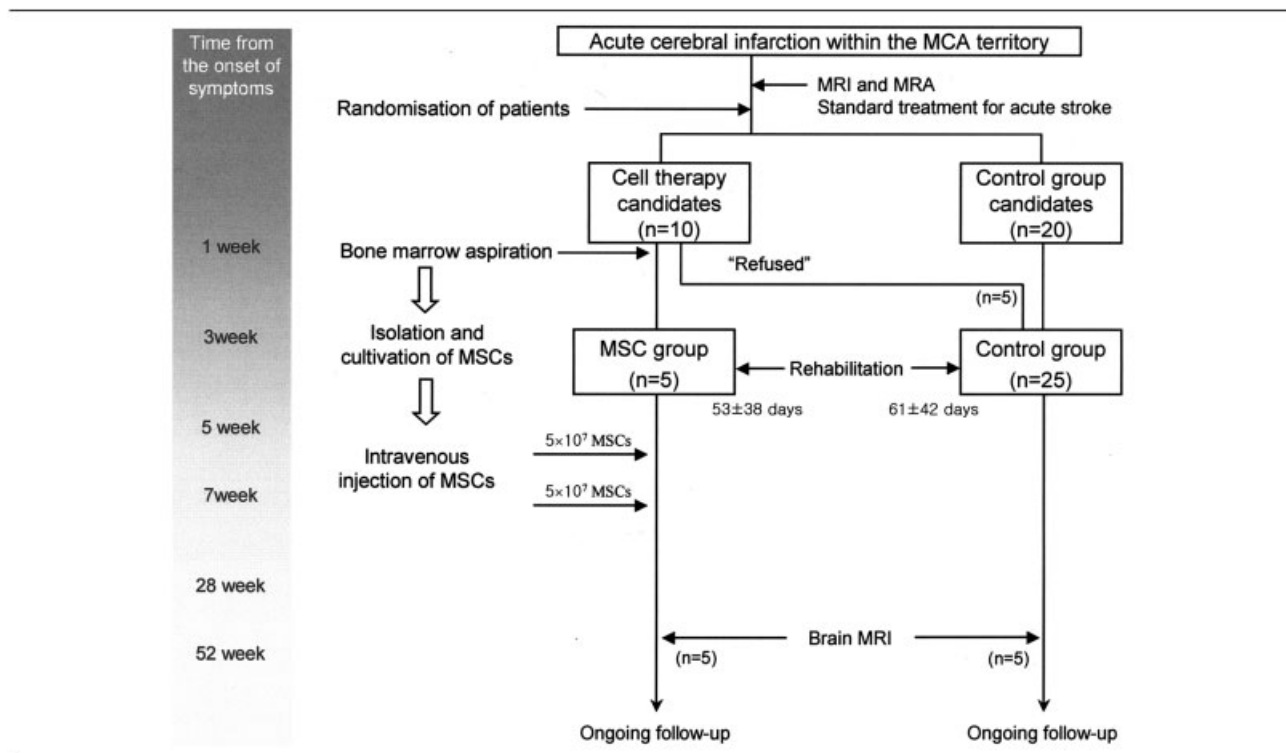


Fig 1. Study protocol.

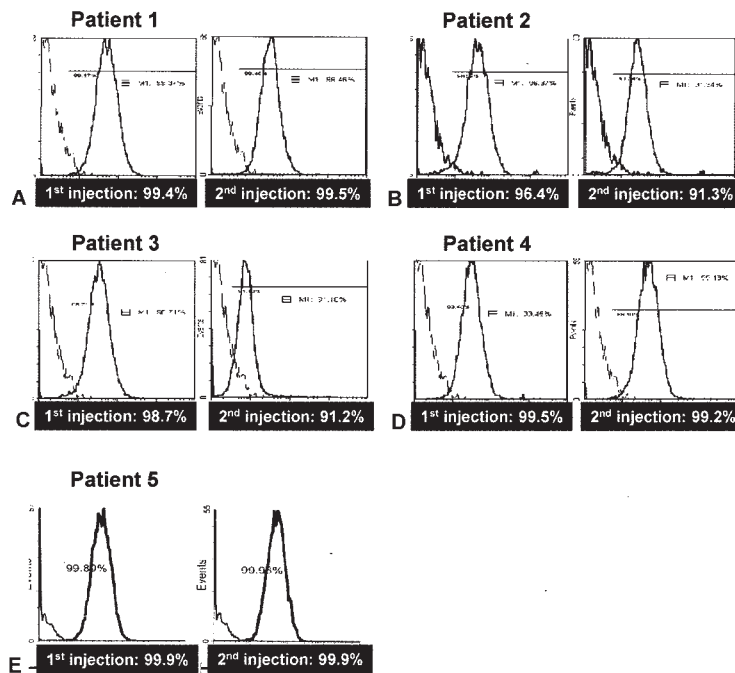


Fig 2. Flow cytometric analysis of the mesenchymal stem cells of each patient with antibody directed against SH-2 (CD105). Left histogram of each analysis indicates isotype control.

and high expression levels of SH antigens (>91% of cells; Fig 2). These cells did not express CD34, CD45, human leukocyte antigen-D related, or class I human leukocyte antigen (not shown). Cell viability was determined by trypan blue staining at the end of the harvest and before infusion; viability was greater than 95% for every infusate at both time points. Cell cultures were tested weekly for sterility; there was no evidence of bacterial, fungal, viral, or mycoplasmal contamination in any of the flasks tested. We used GMP (Good Manufacturing Practice) conditions (FCB-Pharmicell Co Ltd, Sungnam, South Korea) and clinical grade reagents for preparation of the cells.

On the day of injection, the cells were harvested using trypsin, washed with phosphate-buffered saline, and resuspended in 10ml saline. Freshly harvested autologous MSCs were infused into patients through the port of a running intravenous infusion of 50 to 80 ml saline into a peripheral catheter over 15 to 20 minutes. MSC-treated patients received 5×10^7 cells twice: 4 to 5 (first boosting) and 7 to 9 weeks (second boosting) after symptom onset (see Fig 1).

Measurement of Improvements and Adverse Effects

All patients were evaluated according to a protocol that included demographic data, medical history, vascular risk factors, and stroke scales, as in our previous study.¹³ Patients were evaluated for safety and efficacy at admission and at 1, 4 to 5 (first boosting), 7 to 9 (second boosting), 14, 28, and 52 weeks after admission. Brain magnetic resonance imaging (MRI; 1.5 Tesla) was performed in all patients at admission. A follow-up MRI was performed at 52 weeks after the onset of symptoms in all MSC-treated patients and in 5 control patients. Volumetric analysis was performed to measure the

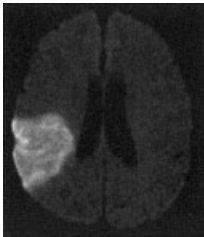
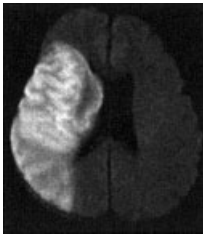

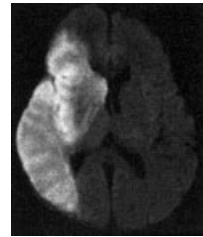
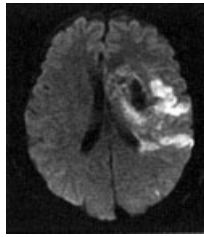
volumes of the infarcted areas (using initial DWI and fluid-attenuated inversion recovery image at follow-up) and the lateral ventricle (using T2-weighted imaging). Volumes were computed by multiplying the measured area per slice by the section thickness (slice thickness, 4mm; gap, 1mm). These analyses were performed by technicians who were blind to the group allocation and clinical data. The NIHSS score, the Barthel index (BI), and the modified Rankin Scale (mRS) were checked serially by a neurologist who was blind to the group allocation and radiological data.

We assessed the safety of intravenous autologous MSC infusion by the development of an immediate or a delayed reaction. Immediate reaction included allergic reactions (tachycardia, fever, skin eruption, leukocytosis), local complications (hematoma, local infection at the site of bone marrow aspiration), vascular obstruction (tachypnea, oliguria, peripheral vascular insufficiency, recurrence of stroke), and systemic complications (systemic infections, increased aspartate aminotransferase and alanine aminotransferase or blood urea nitrogen/creatinine levels). To evaluate tumor formation as a delayed reaction, we performed a physical evaluation, a visual inspection of the skin and oral mucosa, and a follow-up MRI.

Statistical Analysis

Differences between the groups with respect to the clinical and radiological features and the prognoses were examined using χ^2 , Fisher's exact, and Student's *t* test or a one-way analysis of variance. Statistical significance was established at $p < 0.05$.

Table 1. Characteristics of Patients of the MSC Group

Characteristic	Patient 1	Patient 2	Patient 3	Patient 4	Patient 5
Sex/age	M/66	M/54	F/58	M/72	M/68
Risk factor	Smoking, stroke history	Hypertension, smoking	Diabetes	Hypertension, Smoking	Atrial fibrillation
Symptoms	Agnosia and hemiparesis	Agnosia and hemiparesis	Agnosia and hemiparesis	Agnosia and hemiparesis	Aphasia and hemiparesis
Infarct location on DWI					
NIHSS at admission	7	12	10	10	14
Time onset to MSC infusion	41 day	55 day	44 day	32 day	61 day
No. of injected cells	5×10^7 , two times	5×10^7 , two times	5×10^7 , two times	5×10^7 , two times	5×10^7 , two times
Acute treatment	Conservative	Conservative	Conservative	Conservative	Thrombolytics
Preventive medication	Aspirin and clopidogrel	Aspirin and clopidogrel	Aspirin and clopidogrel	Aspirin	Warfarin

MSC = mesenchymal stem cell; DWI = diffusion-weighted magnetic resonance imaging; NIHSS = National Institutes of Health Stroke Scale.

Results

Patient Characteristics

The clinical and neuroradiological characteristics of the MSC group are presented in Table 1.

Because of the experimental nature of the treatment, only five patients of the MSC group were included in this study. All individuals had massive cerebral infarcts that involved cortex within the MCA territory as documented by DWI, and all patients had cortical dysfunction on neurological examination. All patients had at least one risk factor for stroke, and all were severely disabled despite appropriate treatment during the acute stage of stroke.

The clinical and radiological characteristics of the control group were not significantly different from those of the MSC group (Table 2). The sex ratio was the same in both groups. Control patients were significantly younger than those of the MSC group ($p = 0.046$). The risk factors for stroke and mechanisms of stroke were similar in both groups. The NIHSS score on admission, the BI and mRS score on the seventh day of admission, and the DWI lesion volume were not different between the groups ($p > 0.05$).

Safety

Clinical, laboratory, and radiographic evaluations of the MSC-treated patients showed no deaths, stroke recurrence, or cell-related serious adverse events. There was no immediate or delayed toxicity related to intra-

venous MSC infusion during the therapeutic window or within the 1-year follow-up period. One patient (Patient 5) experienced development of cellulitis in his right foot 6 months after MSC infusion; this was caused by tinea pedis and was treated with antifungal agents.

Functional Outcome

The NIHSS score as an index of neurological deficit and the BI and mRS as indices of functional recovery were administered at regular intervals for up to 1 year after the onset of stroke. Despite similar baseline values, the BI of MSC-treated patients after MSC infusion was greater than that of the control patients ($p = 0.011$, 0.017 , and 0.115 at 3, 6, and 12 months, respectively; Fig 3). Similarly, there was a tendency for a lower mRS score in the MSC group than in the control group ($p = 0.076$, 0.171 , and 0.286 at 3, 6, and 12 months, respectively; Fig 4), although this difference was not statistically significant.

In MSC-treated patients, the BI increased dramatically after the MSC infusion, from 9.0 ± 20.1 (mean \pm SD) on the seventh day of admission and 29.0 ± 23.6 on the day of the first injection to 55.0 ± 17.0 , 62.0 ± 12.0 , and 62.0 ± 20.8 at 3, 6, and 12 months after the onset of symptoms, respectively. By contrast, changes in the NIHSS scores were less prominent than were changes in the BI. Although all the scores of MSC-treated patients improved according to

Table 2. Clinical Characteristics at Baseline

Characteristic	Control Group (n = 25)	MSC Group (n = 5)	p
Age, mean ± SD	59.3 ± 11.5	63.0 ± 7.5	0.046
Male sex	14 (56%)	4 (80%)	0.622
Severity of illness, mean ± SD			
NIHSS on admission	11.6 ± 4.9	10.6 ± 2.6	0.104
Barthel index at seventh day	13.4 ± 22.2	9.0 ± 20.1	0.731
Modified Rankin score at seventh day	4.6 ± 0.7	4.8 ± 0.5	0.516
DWI lesion volume (ml)	89.1 ± 77.4	127.4 ± 70.3	0.180
Risk factors			
Hypertension	17 (68%)	2 (40%)	0.327
Diabetes	2 (8%)	1 (20%)	0.433
Smoking	7 (28%)	3 (20%)	0.143
Hyperlipidemia	6 (24%)	0 (0%)	0.553
Atrial fibrillation	2 (8%)	1 (20%)	0.433
Previous stroke history	7 (28%)	1 (20%)	0.640
Stroke mechanisms			1.000
Atherosclerotic	17 (68%)	4 (80%)	
Cardioembolic	5 (20%)	1 (20%)	
Cryptogenic	3 (12%)	—	
Treatment			
Duration of rehabilitation therapy, days	53.4 ± 38.2	61.2 ± 42.0	0.686
Thrombolytics	5 (20%)	1 (20%)	
Drugs	AP 19, AC 6	AP 4, AC 1	

MSC = mesenchymal stem cell; SD = standard deviation; DWI = diffusion-weighted magnetic resonance imaging. NIHSS = National Institute of Health Stroke Scale; AP = antiplatelet agent; AC = anticoagulant.

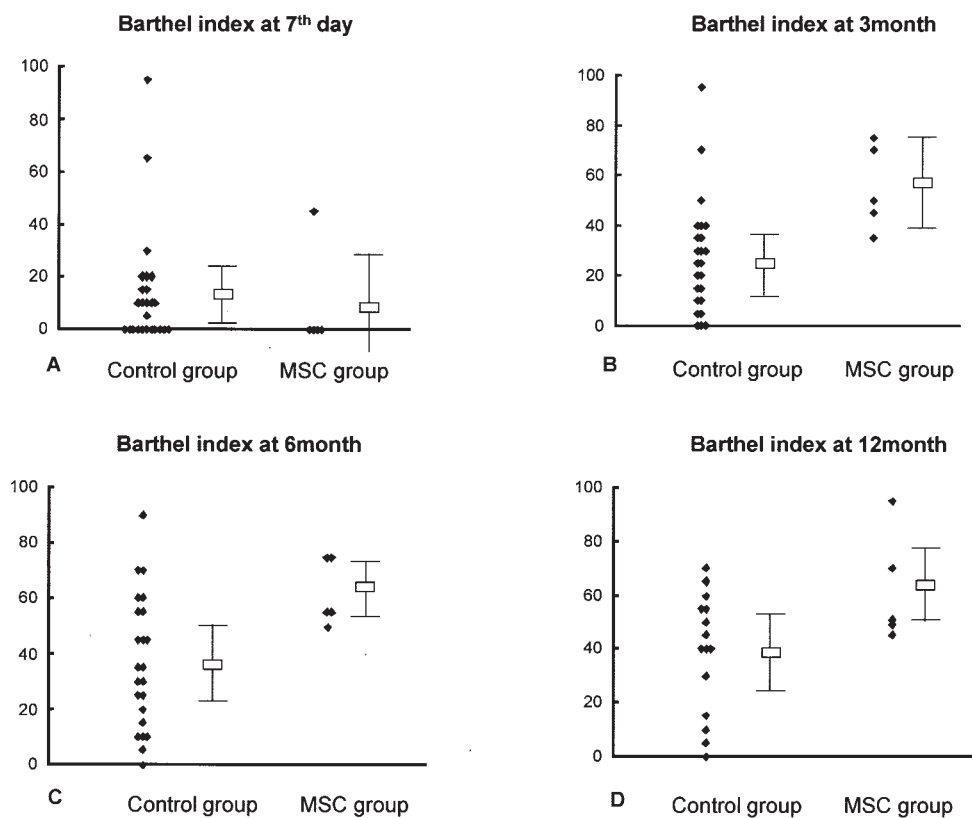


Fig 3. The Barthel index before (day 7) and after (3, 6, and 12 months) cell therapy.

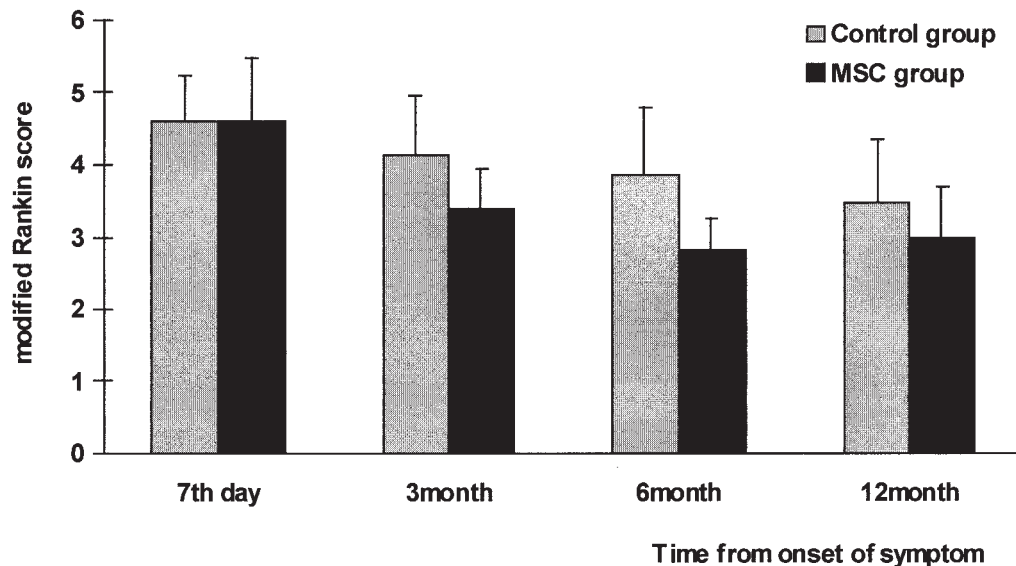


Fig 4. The modified Rankin score before (day 7) and after (3, 6, and 12 months) cell therapy.

the NIHSS (mean \pm SD: 4.2 ± 0.5 ; range, 4–5), the degrees of improvement from the day of first boosting until 1 year after the onset of symptoms were not substantial (mean \pm SD, 2.0 ± 1.4 ; range, 1–4).

Imaging

Serial MRI was performed at 12 months after the onset of symptoms in all patients. No patients showed any structural changes (including tumor formation) within the brain after the MSC infusion relative to baseline. The volumetric analysis indicated that the magnitude of apparent changes in infarct volume between the initial DWI and the follow-up MRI were not different between the groups ($p = 0.661$; Fig 5A, C). However, atrophy within periinfarct areas and secondary dilations of the adjacent ventricle were less prominent in MSC-treated patients than in the control patients (see Fig 5B,C).

Discussion

It remains uncertain which type of cell would be most appropriate for transplantation into stroke patients. Various cell types (eg, porcine fetal cells, embryonic stem cells, and immortalized neuronal cells and bone marrow stromal cells) are being investigated. However, the ethical dilemmas of embryonic stem cell research and the problems associated with allotransplantation and xenotransplantation limit the clinical use of stem cells. Recent experimental studies raised the possibility of using MSCs as stroke therapy. There is increasing evidence that MSCs promote functional recovery in animal models of ischemic stroke. First, unlike hematopoietic stem cells, MSCs adhere to plastic and cause a variety of tissue/cell types, including bone, cartilage,

adipose, muscle, hepatocytes, glia, and neurons.^{14–17} In specific culture conditions, human MSCs can differentiate into cells that express markers of neuronal progenitor cells¹⁴ and can engraft and migrate along paths that resemble those of neuronal progenitor cells.¹⁵ It is still controversial, however, whether spontaneous cell fusion^{18,19} or true differentiation^{20,21} was the primary cause for these unexpected cell outcomes. Second, MSCs are eminently suitable for human trials because these cells can be obtained readily from bone marrow under local anesthesia, are easily expanded by culture, and potentially could be delivered to injured brain tissue without the need for invasive stereotaxic operations.⁷ This is in contrast to hematopoietic stem cells, which reportedly experience a dramatic decline in homing capacity after culture expansion.²² Moreover, the use of patients' own bone marrow cells should circumvent the problems of host immunity and graft-versus-host disease. In this study, we assessed the use of autologous MSCs as therapy for ischemic stroke.

Chen and colleagues⁴ introduced the idea of a relation between cell dose and effect after finding that animals with ischemia-induced brain damage infused with a high dose of MSCs (3×10^6) recovered better than did control animals infused with a low dose of MSCs (1×10^6). Adult mononuclear bone marrow cells contain few ($\leq 1\%$) stem cells. Moreover, parenteral injection distributes MSCs to other organs (including muscle, spleen, kidney, lung, and liver), which further decreases the number of cells that reach the brain.²³ The limited number of available MSCs requires that there be a process to isolate and increase the number of these cells *ex vivo*. Although rare (1 per 10^6 bone marrow mononuclear cells), MSCs proliferate

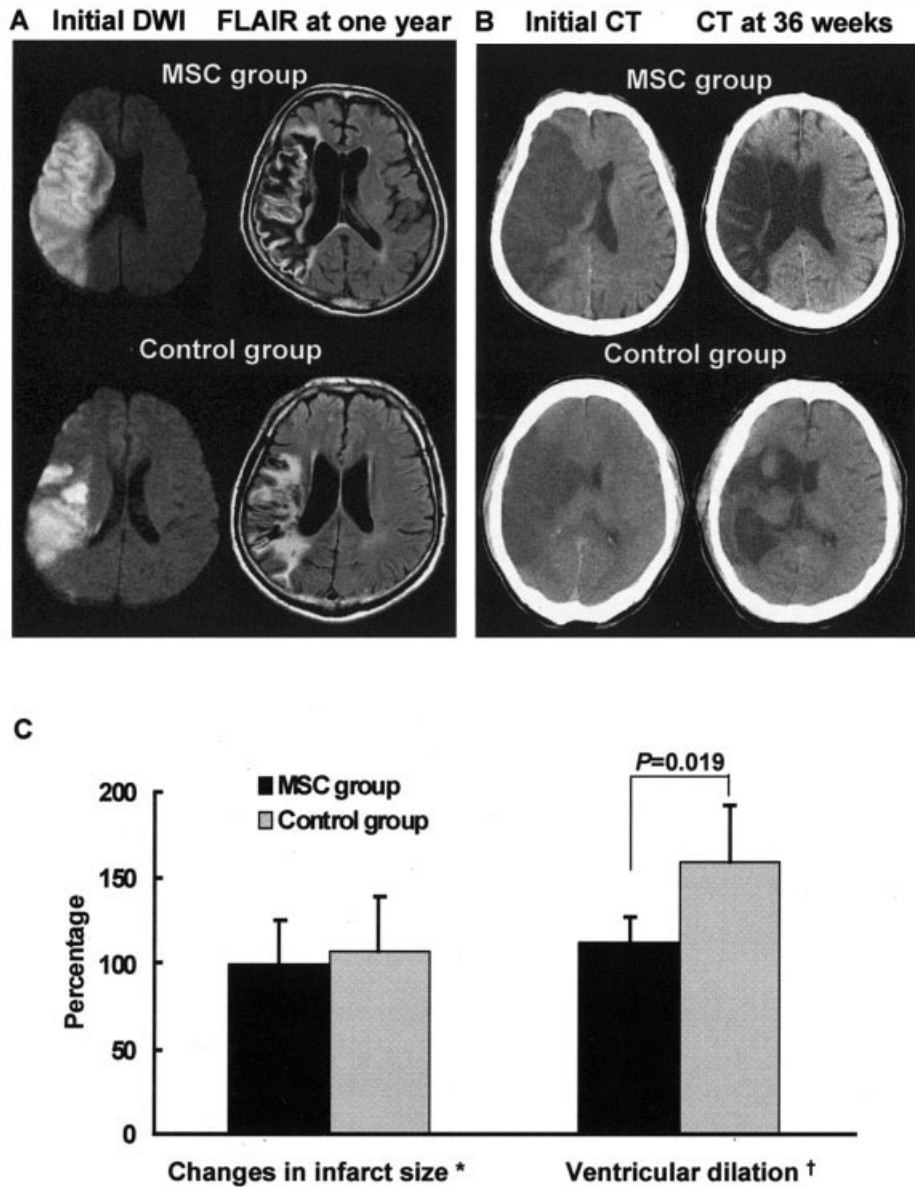


Fig 5. Neuroimaging findings. Changes in infarct volume were not observed in both groups (A), but ventricular dilations secondary to atrophic changes of perinfarct area were more prominent in the control group than in the mesenchymal stem cell group (B). (C) Volumetric analysis of infarct size (left) and ventricular size (right). Asterisk indicates volume ratio of lesions on fluid-attenuated inversion recovery image performed at 1 year after symptom onset to initial diffusion-weighted imaging lesions. Dagger indicates volume ratio of the lateral ventricle of symptomatic side to the contralateral lateral ventricle.

rapidly in vitro (48–72 hour doubling time) and have been expanded by more than 60 cell doublings.²⁴ Considering these facts, we decided to transplant MSCs at a dose that had been shown to be effective in rats. Although the stem cells are highly prone to differentiation, our flow cytometry data indicated that the culture-expanded MSCs had a high level of expression of MSC surface markers (SH-2 and -4).

The therapeutic modalities that would offer MSCs the best chance to reach the brain include intraarterial delivery, as in patients with myocardial infarcts,^{1,2} or

intralesional implantation, as in animal models of ischemic stroke.^{11,12} However, intraarterial infusion of high doses of cells and angiography itself may cause adverse effects, including recurrent stroke.²⁵ Moreover, surgical procedures in patients with severely disabling stroke are often impossible and exacerbate the patient's state. In addition, animal experiments have demonstrated that behavioral recovery after both intracarotid and intralesional administration of bone marrow stromal cells was similar to that after intravenous administration.^{4,7,11}

The optimal time at which MSC infusion should occur after a stroke is unknown. In animal studies, cells have been injected from one day to one month after MCA occlusion, and few investigations have examined whether transplantation at different times after ischemic damage affects proliferation, differentiation, integration, and functional outcome. Transplantation to an acute infarct would be unlikely to succeed if there were severe arterial occlusions, because blood flow would be inadequate to support donor cell viability. In addition, the release of excitotoxic neurotransmitters, free radicals, and proinflammatory mediators might threaten cells introduced into the periinfarct region. The timing of transplantation also must consider the natural course of recovery from stroke. Many neurologists would delay transplantation until deficits reached a plateau. For these reasons, we studied patients who remained severely disabled 1 week after a stroke, and the MSC infusion was performed in all the patients more than 1 month after the onset of stroke symptoms. Additional studies concerning the time of transplantation are needed because unnecessarily delaying the procedure allows for the formation of scar tissue, which might adversely affect implanted grafts.

This report is the first to describe the successful isolation, *ex vivo* culture expansion, and intravenous infusion without toxicity of autologous MSCs into patients with ischemic stroke. Despite the large size of MSCs and the *ex vivo* culture expansion of these cells, there was neither immediate nor delayed infusion-related toxicity associated with the infusion of 1×10^8 MSCs. The clinical use of culture-expanded MSCs and the safety of MSC infusion have already been reported for patients with cancer¹⁰ and osteogenesis imperfecta.²⁶ Our results indicate that this form of cell therapy is feasible and may have beneficial clinical and radiological effects in patients with MCA territorial infarcts and with severe neurological sequelae. In patients with breast cancer, circulating clonogenic MSCs have been observed up to 60 minutes after infusion, which suggests that these cells might be distributed to and survive in tissues.¹⁰ Our clinical and neuroimaging data suggest that transplanted cells are highly viable. All outcome measurements were consistent in identifying a trend toward improved scores in tests of functional recovery in patients treated with MSCs. Less prominent atrophy was a consistent finding on serial MRI scans in patients treated with MSCs. However, our results should be interpreted with caution because only five patients were treated with MSCs in this study, and stroke outcomes are extraordinary heterogeneous among patients, even those with identical vascular and neurological insults.

Because we could not examine brain pathology, we were unable to determine the mechanisms by which MSCs facilitate recovery from stroke. Rather than re-

place infarcted tissue, MSCs may up-regulate endogenous recovery mechanisms either at the periinfarct area (neurogenesis) or at areas that are remote from the infarct (neuronal plasticity). Chen and colleagues⁴ suggest that the mechanism of MSC-induced recovery may be related to the production of trophic factors released by the MSCs. Our results support this possibility: functional recovery (improvement in the BI and mRS score) was not accompanied by a diminution of neurological deficits (there was a less prominent improvement in the NIHSS score), and functional improvement occurred shortly after cell therapy. In addition, the MRI scans of the MSC group showed less prominent atrophy throughout the brain including the periinfarct zones, which was consistent with a diffuse action of MSCs throughout the brain. We hope to obtain a better understanding of the mechanisms of action of MSCs from ongoing neuroimaging studies (diffusion tensor imaging and positron emission tomography).

Our findings indicate that intravenous injection of *ex vivo*-cultured autologous MSCs is a safe and feasible method of treatment for ischemic stroke. Double-blind studies with larger cohorts are needed to reach a definitive conclusion regarding the efficacy of MSC therapy. In addition, further studies are needed to determine which stroke patients should undergo transplantation, because the location, severity, and chronicity of the stroke and the adequacy of blood supply will likely affect the efficacy of MSC therapy.

This work was supported by the Korea Research Foundation (KRF-2003-E00228, O.Y.B.) and the Korea Health 21 R&D Project, Ministry of Health and Welfare, Republic of Korea (0412-DB00-0101-007, O.Y.B., G.L.).

The study would not have been possible without the help of the patients and their families and the generous cooperation of doctors and nurses at Ajou University Hospital.

References

1. Strauer BE, Brehm M, Zeus T, et al. Repair of infarcted myocardium by autologous intracoronary mononuclear bone marrow cell transplantation in humans. *Circulation* 2002;106:1913–1918.
2. Tse HF, Kwong YL, Chan JK, et al. Angiogenesis in ischaemic myocardium by intramyocardial autologous bone marrow mononuclear cell implantation. *Lancet* 2003;361:47–49.
3. Tateishi-Yuyama E, Matsubara H, Murohara T, et al. Therapeutic Angiogenesis using Cell Transplantation (TACT) Study Investigators. Therapeutic angiogenesis for patients with limb ischaemia by autologous transplantation of bone-marrow cells: a pilot study and a randomised controlled trial. *Lancet* 2002;360:427–435.
4. Chen J, Li Y, Wang L, et al. Therapeutic benefit of intravenous administration of bone marrow stromal cells after cerebral ischemia in rats. *Stroke* 2001;32:1005–1011.
5. Eglitis MA, Dawson D, Park KW, Mouradian MM. Targeting of marrow-derived astrocytes to the ischemic brain. *NeuroReport* 1999;10:1289–1292.

6. Chen J, Li Y, Katakowski M, et al. Intravenous bone marrow stromal cell therapy reduces apoptosis and promotes endogenous cell proliferation after stroke in female rat. *J Neurosci Res* 2003;73:778–786.
7. Li Y, Chen J, Chen XG, et al. Human marrow stromal cell therapy for stroke in rat: neurotrophins and functional recovery. *Neurology* 2002;59:514–523.
8. Zhao LR, Duan WM, Reyes M, et al. Human bone marrow stem cells exhibit neural phenotypes and ameliorate neurological deficits after grafting into the ischemic brain of rats. *Exp Neurol* 2002;174:11–20.
9. Kondziolka D, Wechsler L, Goldstein S, et al. Transplantation of cultured human neuronal cells for patients with stroke. *Neurology* 2000;55:565–569.
10. Koc ON, Gerson SL, Cooper BW, et al. Rapid hematopoietic recovery after coinfusion of autologous-blood stem cells and culture-expanded marrow mesenchymal stem cells in advanced breast cancer patients receiving high-dose chemotherapy. *J Clin Oncol* 2000;18:307–316.
11. Li Y, Chen J, Chopp M. Adult bone marrow transplantation after stroke in adult rats. *Cell Transplant* 2001;10:31–40.
12. Li Y, Chopp M, Chen J, et al. Intrastratial transplantation of bone marrow nonhematopoietic cells improves functional recovery after stroke in adult mice. *J Cereb Blood Flow Metab* 2000;20:1311–1319.
13. Bang OY, Lee PH, Joo SY, et al. Frequency and mechanisms of stroke recurrence after cryptogenic stroke. *Ann Neurol* 2003;54:227–234.
14. Sanchez-Ramos J, Song S, Cardoza-Pelaez F, et al. Adult bone marrow stromal cells differentiate into neural cells in vitro. *Exp Neurol* 2000;164:247–256.
15. Woodbury D, Schwartz EJ, Prockop DJ, Black IB. Adult rat and human bone marrow stromal cells differentiate into neurons. *J Neurosci Res* 2000;61:364–370.
16. Prockop DJ. Marrow stromal cells as stem cells for nonhematopoietic tissues. *Science* 1997;276:71–74.
17. Azizi SA, Stokes D, Augelli BJ, et al. Engraftment and migration of human bone marrow stromal cells implanted in the brains of albino rats—similarities to astrocyte grafts. *Proc Natl Acad Sci U S A* 1998;95:3908–3913.
18. Terada N, Hamazaki T, Oka M, et al. Bone marrow cells adopt the phenotype of other cells by spontaneous cell fusion. *Nature* 2002;416:542–545.
19. Ying QL, Nichols J, Evans EP, Smith AG. Changing potency by spontaneous fusion. *Nature* 2002;416:545–548.
20. Cogle CR, Yachnis AT, Laywell ED, et al. Bone marrow transdifferentiation in brain after transplantation: a retrospective study. *Lancet* 2004;363:1432–1437.
21. Tondreau T, Lagneaux L, Dejeneffe M, et al. Bone marrow-derived mesenchymal stem cells already express specific neural proteins before any differentiation. *Differentiation* 2004;72:319–326.
22. Szilvassy SJ, Bass MJ, Van Zant G, Grimes B. Organ-selective homing defines engraftment kinetics of murine hematopoietic stem cells and is compromised by ex vivo expansion. *Blood* 1999;93:1557–1566.
23. Hendriks PJ, Martens CM, Hagenbeek A, et al. Homing of fluorescently labeled murine hematopoietic stem cells. *Exp Hematol* 1996;24:129–140.
24. Reyes M, Lund T, Lenvik T, et al. Purification and ex vivo expansion of postnatal human marrow mesodermal progenitor cells. *Blood* 2001;98:2615–2625.
25. Vulliamy PR, Greeley M, Halloran SM, et al. Intra-coronary arterial injection of mesenchymal stromal cells and microinfarction in dogs. *Lancet* 2004;363:783–784.
26. Horwitz EM, Prockop DJ, Fitzpatrick LA, et al. Transplantability and therapeutic effects of bone marrow-derived mesenchymal cells in children with osteogenesis imperfecta. *Nat Med* 1999;5:309–313.